

*American Handbook of Psychiatry*

**INTERSEXUAL AND TRANSEXUAL  
BEHAVIOR AND SYNDROMES**

**JOHN MONEY**

# **INTERSEXUAL AND TRANSEXUAL BEHAVIOR AND SYNDROMES**

**John Money**

e-Book 2016 International Psychotherapy Institute

From *American Handbook of Psychiatry: Volume 3* Silvano Arieti

Copyright © 1974 by Silvano Arieti and Eugene B. Brody

All Rights Reserved

Created in the United States of America

## Table of Contents

### INTERSEXUAL AND TRANSEXUAL<sup>1</sup> BEHAVIOR AND SYNDROMES

Determinants of Gender Identity Differentiation

Ambiguous Gender Identity and Sex Reassignment

Avoidance of Ambiguous Gender Identity

Puberty and Gender Identity

Personal Erotic Arousal Imagery

Transsexual Sex Reassignment

Sex Reassignment: Rationale and Probationary Period

Differential Diagnosis

Hormonal Reassignment: Male

Hormonal Reassignment: Female

Surgical Treatment

Gender Identity Differentiation: Hypothesis

Concluding Remarks

Bibliography

# INTERSEXUAL AND TRANSEXUAL<sup>1</sup> BEHAVIOR AND SYNDROMES

**John Money**

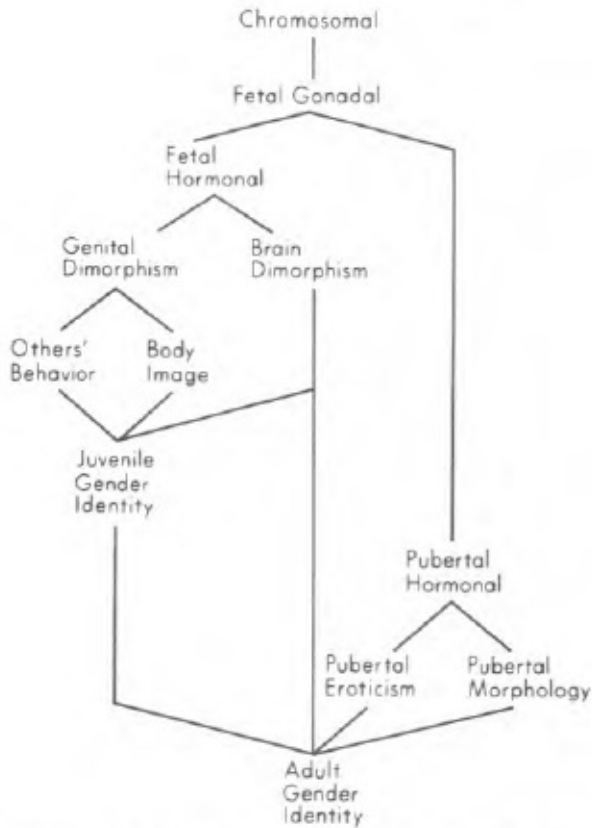
Intersexuality is of a significance for psychiatry disproportionate to the demand it creates for psychiatric service, essential though that service is. Its significance lies in the fact that human intersexuality is the clinical complement, and the only one in human beings, of experimental animal studies into the differentiation of gender-related behavior and gender identity.

## **Determinants of Gender Identity Differentiation**

Studies in intersexuality show that the sex chromosomes, or indeed any of the chromosomes, do not, of and by themselves alone, have a direct line of influence on the dimorphism of gender identity and gender behavior. The chromosomes exert their influence only indirectly, as the first link in a chain or sequence of determinants (Figure 16-1).

The second link is the fetal gonad which, from a bipotential beginning, differentiates at six weeks of gestation as a testis, when the sex chromosomes are XY, or at twelve weeks as an ovary, when the sex chromosomes are XX. It

is from this stage of differentiation that the traditional nomenclature of intersexuality derives. True hermaphroditism occurs when the bipotentiality of the indifferent gonad does not resolve, but issues in ovotestis, or ovary and testis —the chromosomes are usually 46,XX, but may be mosaic or in some other way anomalous. Male hermaphroditism or pseudohermaphroditism (the “pseudo” is superfluous, for all forms of hermaphroditism are genuine) occurs when only testicular structure, even though imperfect, is present, ambiguity residing elsewhere in the reproductive anatomy. Similarly, for female hermaphroditism (pseudohermaphroditism), only ovarian tissue is present, with ambiguity elsewhere in the system. Female hermaphrodites are almost invariably 46,XX chromosomally; whereas some male hermaphrodites may be not the expected 46,XY, but a mosaic like 46,XY/45,X.



**Figure 16-1.**  
Sequence of determinants of adult gender identity.

The third link in the chain of gender identity differentiation is hormonal. It is actually a bifurcated link, connecting with both the genital morphology and the central nervous system. In normal fetal development, hormonal differentiation is a function of the fetal gonad. More accurately, it is a function

of the fetal testis: Whereas hormones from the fetal testis are essential for the morphologic differentiation of a male, no sex hormone whatsoever is necessary for the differentiation of a morphologic female. Nature's primary archetype is the female; the male depends on the principle of something added. There are two masculinizing substances released by the fetal testis. One, known only by its function, is the mullerian inhibiting substance. Without it, the male is born with the mullerian ducts differentiated into a uterus and fallopian tubes, as in the female. The other fetal testicular substance is androgen, the male sex hormone, essential for differentiation of the internal masculine reproductive tract, and essential also for the differentiation of the external sexual *Anlagen* into male structures, instead of their female homologues, that is the clitoris, clitoral hood plus labia minora, and labia majora, instead of, respectively, the penis, penile skin covering, and scrotum.

Fetal androgen has also an action on the central nervous system in the region of the hypothalamus. This effect has been well demonstrated experimentally in various laboratory species, especially rodents, that have estrous cycles. Androgenization of the fetal hypothalamus, during the critical developmental period, prevents subsequent cycling of the pituitary, and thus of the gonadal hormones in adulthood. This effect is independent of genetic sex. Removal of androgen from the male before the critical period permits pituitary cycling to occur subsequently, as can be demonstrated if ovarian



tissue is experimentally implanted in the aqueous chamber of the animal's eye.

The neural mechanisms of cyclicity have been experimentally located with a fair degree of certainty in the posterior region of the hypothalamus. Other neural centers governing behavioral patterns associated with hormonal cycling, or non-cycling, in adulthood are situated in the anterior region of the hypothalamus. There is less actual experimental certainty of an androgenizing effect on these centers, but a good deal of presumptive experimental evidence which is not confined to rodents and lower species but extends also to the primates.

Among the primates, including man, sexually dimorphic, fetally androgen-determined behavior manifests itself in juvenile play. Animal-experimental and human-clinical evidence suggests that vigorous, athletic energy expenditure (tomboyism, in girls) is one such form of play. Challenging or defending a position in the dominance hierarchy is another. Play-rehearsal of sexual, pelvic thrusting movements may be another. On the negative side, absence of maternalism in rehearsal-play is also a masculine trait, its presence being common in girls. At puberty, and in especially the beginning of adolescence, there is also a likelihood that boys more easily than girls are genitally arousable by visual and narrative materials, independently of sentimentalism and the sense of touch.

None of these androgen-dependent traits is the exclusive prerogative of boys. They can, if present, be incorporated into a feminine gender identity. Conversely, their presence is not a *sine qua non* of a masculine gender identity, though by today's cultural standards in our society it is difficult to be accepted as a "sissy" boy. By contrast, a tomboyish girl is readily acceptable.

The fourth link in the chain of gender identity differentiation is the morphology of the external genitals, itself a product of hormonal differentiation. This is also a bifurcated link, connecting with the behavior of other people and also that of the child. Dimorphism of the external genitalia is a stimulus of extraordinary potency with respect to the program of behavior that it releases from other people. As a new baby is expected, parents and others stay poised, so to speak, with two programs of behavior at the ready, only one of which will be progressively brought into action. It begins with name choice, and continues in countless activities and responses of day-to-day living.

The appearance of the genitalia also influences, eventually, the body image and the program of the child's own gender behavior by reinforcing the self-sex concept, as a boy or girl. This happens as a child discovers his or her similarity to others of the same sex, and difference from others of the opposite sex.

## Core Gender Identity

Like a loop that links together the social and, later, the personal effects of genital morphology with fetal-hormonal brain effects, personal gender identity (see Figure 16-1) begins to emerge in late infancy and early childhood, at around the same time as native language becomes established. The core gender identity, to use a recently minted term, becomes differentiated as male or female prior to the developmental phase identified in psychoanalytic doctrine as oedipal, and contemporaneously with the preceding phases, named according to that doctrine the late oral (or more literally, oral-haptic) and the anal. The core gender identity is developmentally neither psychoanalytically oral nor anal in origin, though its differentiation is vulnerable to developmental disturbances, regardless of source, that take place during those early developmental periods of life.

Evidence that postnatal development is critical in gender identity differentiation is especially clear in the case of matched pairs of hermaphrodites homogeneous for diagnosis and etiology,<sup>2</sup> but heterogeneous for sex of rearing. Then, gender identity typically differentiates in conformity with assigned sex. The predictability of this outcome is enhanced if parental anxiety and uncertainty are dispelled, and if surgical correction of the external genitalia in conformity with assigned sex is achieved as early as possible.

In the case of sex assignment as a girl, stage one of surgical feminization, the removal of a too-large phallic protuberance, can be accomplished as early as the second week of life. If no vaginal cavity is present, the construction of one by means of plastic surgery is best postponed until after full growth has been achieved in middle-to-late teenage.

In the case of sex assignment as a boy, surgical repair of an incompletely formed phallic protuberance usually requires surgical release of the organ to make it pendulous, and the construction of a penile urethra. The procedure fails if the organ is not big enough to begin with. Consequently, many genetic and gonadal male intersexes should be assigned and surgically repaired as females.

Surgical repair as a male cannot be accomplished as early as repair as a female. Therefore, it is doubly important, when the decision is to assign an intersexed baby as a boy, to guarantee the education of the parents as to the whys and wherefores of their baby's intersexuality, and the program of its case management and prognosis. Otherwise, there is a high risk that ambiguity of genital appearance will generate ambiguity or uncertainty of rearing, as ostensibly a boy or girl, which in turn will generate ambiguity or uncertainty of gender identity in the child.

## **Ambiguous Gender Identity and Sex Reassignment**

The intersexed child most likely to grow up with an ambiguous gender identity is one with uncorrected, ambiguous-looking genitalia, raised under a shadow of doubt as to whether the sex had been correctly declared at birth. The doubt may have emanated either indirectly from the medical profession, or directly. There are still some misinformed physicians who say, quite incorrectly, that the correct declaration cannot be made until nature plays her hand at puberty.

Statistically speaking, intersexed babies most likely to grow up to differentiate an ambiguous gender identity leading to a request for sex reassignment have a small, imperfectly formed (hypospadiac) phallus, atrophic or barely palpable gonads presumed to be testes, and an assigned sex as a provisional female. The provisional or equivocal nature of the sex of assignment, without surgical feminization, reflects lack of up-to-date criteria in the knowledge of specialist consultants at the time of birth. On the one hand, common sense dictates that a baby with little more than a clitoral-sized phallus and urogenital sinus should be a girl. On the other hand, presumed testes suggest, to the uninformed, a quasi-moralistic obligation to declare the baby as a boy. A compromise, misguided though it is, is to declare the baby as a girl, while waiting to see what happens at puberty.

If, meantime, the ambiguous pendulum of the child's gender identity differentiation swings in the male direction, and if at puberty she undergoes

hormonal masculinization, then she will, after a long overdue diagnostic verification as a genetic and gonadal male, almost certainly be permitted a sex reassignment if she requests it, though she may be denied the request to continue living as a girl. Here again, there is a quasi-moralistic element in the decision, on the basis of the criterion of the gonads. The case that illustrates the converse is that of a very similar but genetically female intersexed child with the precociously pubertal, adrenal virilization of the adrenogenital syndrome. It is not too common, because of lack of palpable gonads, for such a child to be assigned as a male. When the neonatal diagnostic workup is incomplete, however, assignment as a female may be left surgically unconfirmed, and also unconfirmed by corrective hormonal therapy with cortisone. In that case, the child will grow up with a masculine puberty, and premature to boot. Should her gender identity differentiation have been more masculine than feminine, leading her to request sex reassignment, the request is likely to be denied, though wrongly so. The reason for the denial is that many medical professionals have a feeling, moralistically rather than empirically based, that an individual with two ovaries, a large phallus— even though large enough to be corrected into a functional penis—and a pubertally virilized physique, should not be permitted elective rehabilitation as a man, after having been originally registered as a female. Instead, she should be required to accept surgical feminization of the external genitalia, and hormonal feminization (adequate but not total) of the physique, as a sequel to

corrective hormonal therapy with cortisone. The folly of such an imposition is that it is not maximally rehabilitative: The person who would have succeeded in life as an infertile male and husband is required to fail in life as a fertile female who is, with respect to erotic responsiveness, to all intents and purposes an iatrogenic lesbian, albeit inadvertently so.

The parallel of iatrogenic lesbianism, as above, occurs in a genetic male with a micropenis—hypospadiac and lacking or partially lacking corpora cavernosa—assigned as a boy and failing to masculinize at puberty, as a result of complete testicular failure. If a boy with intersexuality of this type grows up with an ambiguous gender identity, plus the conviction that he can resolve it only by sex reassignment to live as a girl, his atrophic, sterile testes and male chromosomal status are likely to prove a stumbling block. He may be required to take male hormone therapy for masculinization of the physique. It will not change his gender identity. If his only erotic attraction is toward males, then he is, on that criterion, an inadvertent iatrogenic male homosexual, who could have succeeded better in life in the role of a woman.

A boy with similar intersexual status, except that he feminizes and grows breasts at puberty, may also be placed in a similar predicament. It has in the past been easier for many physicians to reconcile themselves to removal of breasts and attempted construction of a penis that will never be capable of erection, than to reconcile themselves to removal of feminizing

testes, construction of an artificial vagina, and legal sex reassignment.

Intersexuals of the above type of feminizing male hermaphroditism, assigned at birth as boys, are few. As in all types of intersexuality, their requests for sex reassignment are rare, and chiefly dependent on the element of ambiguity absorbed from their rearing. Diagnostically, their intersexuality represents an incomplete form of the androgen insensitivity, testicular-feminizing syndrome, a genetically transmitted condition in which there is a body-wide inability at the cellular level to respond to the male sex hormone. In the complete form of the syndrome, the genital morphology is not ambiguous, but female, and puberty is exclusively feminizing, except for lack of menstruation, secondary to vestigial formation of the uterus. The breasts develop well. Requests for sex reassignment, despite the masculine genetic and gonadal status, are no more a part of the syndrome than of congenital atresia of the vagina and uterus in a genetic and gonadal female.

### **Avoidance of Ambiguous Gender Identity**

Differentiation of an ambiguous gender identity, with ultimate resolution of the ambiguity in favor of a sex reassignment request, is not restricted to any one form of intersexuality. It occurs in male, female, and true hermaphroditism. It occurs irrespective of status on the criteria of chromosomal, gonadal, and hormonal sex. It occurs in either direction, male-



to-female, or female-to-male, in individuals otherwise homogeneous for diagnosis and prognosis. The two identifiable variables most likely to lead to ambiguous gender identity and sex reassignment as its resolution are (1) therapeutic negligence in resolving ambiguity, in the minds of parents, regarding the sexual status of their genitally deformed baby and the rationale leading to the sex of assignment, and (2) therapeutic delay, beyond the demands of good surgical practice, in correcting the appearance of the external genitalia to agree with the sex of assignment.

The latter applies especially when the decision has been to raise an infant with a large phallic organ, irrespective of chromosomal or gonadal sex, as a girl. With rare exceptions, it is possible to undertake corrective feminization of the external genitalia during the second or third week of life, or soon thereafter. Removal of the phallic structure does not remove the capacity for orgasm in adulthood, if there is a vaginal orifice, naturally formed. In the absence of a vaginal orifice, the prognosis of orgasm after phallic removal is made with less confidence, though the build-up of erotic feeling and pleasure, if the extended perineal area is intact, can always be counted on.

It is fairly standard in today's practice, provided the diagnosis is established neonatally, to assign female hermaphrodites to the female sex. This practice is justifiable, since neonatal feminizing surgery is successful,

even if fetal masculinization had been so extreme as to differentiate the genital tubercle into a penis, with a penile urethra, instead of a clitoris with its hood and labia minora. Fertility as a female and the possibility of pregnancy are preserved. Alternatively, it is also feasible, when the penis is normally formed, to leave it intact, removing the internal organs, planning for a masculine hormonal puberty, which will take place spontaneously, should androgenic adrenal over-activity remain uncorrected. Otherwise, it will be induced with testosterone therapy.

In the case of male hermaphroditism, and also true hermaphroditism, it is a cardinal rule not to assign the newborn baby as a male, unless the malformed phallic organ is large enough to be repaired for efficient masculine erotic function in adulthood. It is desirable to test the phallus of borderline size for sensitivity to male sex hormone by local application of testosterone ointment for a period of a month. If the organ does not respond with increased vascularization and size, the prognosis is for future pubertal feminization. Therefore, the baby should be assigned as a girl, and treated as such surgically and hormonally, with the appropriate timing. There is no serious issue to be argued regarding castration, for the more defective the penis at birth, the greater the likelihood of testes that are infertile, defective, and subject to malignancy in young or middle adulthood.

## **Age, Gender Identity, and Imposed Reassignment**

The ideal decision concerning sex of assignment is not invariably made, as it should be, at the time of an intersexed child's birth. If subsequently a more extensive diagnostic workup is undertaken, it may be deemed desirable that the original decision should be changed. An imposed change of sex during the juvenile years, however, no matter how convincing the rationale, may be as catastrophic for one intersexed child, as for a morphologically normal one, whereas for another one it may be a joyous return from exile in what the child believes to have been the wrong sex. The difference lies in the unitary versus the ambiguous nature of the gender identity that has differentiated, up to the time the reassignment is imposed. Only the child who has differentiated an ambiguous gender identity in the sex of original assignment is able to make the transition of reassignment successfully. This fact has been overlooked by a few misinformed zealots who advocate changing intersexed children's assigned sex, without consideration of the child's gender identity, so as to make the sex of rearing agree with the chromosomal or gonadal sex, or, as they sometimes diffusely and inaccurately call it, the somatic sex.

Close as some cases of forced reassignment of sex come to therapeutic malpractice, they are, nonetheless, of singular scientific value for the empirical light they shed on the timing of gender-identity differentiation. In the first few months of a child's life, if the original declaration of sex is changed, adjustment to the change is one for which the parents, but not the

baby, need help and guidance. Such an early change may be called simply a re-announcement of sex, to distinguish it from a reassignment which, occurring later, involves the child's own cognizance and memory.

By the age of eighteen months to two years, a normally developing child has a concept of himself as a boy, or herself as a girl. The concept is imbedded in the very language the parents use in talking with their child, with its differentiation of the sexes by generic noun (boy-girl, man-woman, brother-sister, mother-father, etc.), by pronoun, and by proper name. The concept of sex difference in the language is supported by the child's visual experience of the difference, clothed and naked. Above all, it is supported by the contingencies of reinforcement that the parents put into action when the child reacts like the little boy, or the little girl, of their own traditions and expectations.

A two-year-old who is subjected to a sex reassignment may subsequently have explicit recall of the event, but probably will not. In the latter case, the period of living in the other sex, prior to the change is not a *tabula rasa*. It leaves its imprint in much the same way as does a native language that falls into disuse and is replaced by another at, say, the age of two. Later in life, that original language will be learned with greater facility than any other foreign language.

The success with which a child will negotiate a sex reassignment imposed at around the second year of life, or later, will depend partly on the success with which the parents, other members of the family, including siblings, and neighbors negotiate it. The older a child becomes, and the more differentiated his or her gender identity, the more arbitrary does a sex reassignment seem to him or her, defective anatomy notwithstanding. An imposed reassignment then turns out to be rehabilitatively negative, for the sense of self as a member of one sex fails to follow the would-be rehabilitative surgical and/or hormonal therapy.

### **Puberty and Gender Identity**

An intersexed child, upon reaching the normal age of puberty, typically does not develop a desire for sex reassignment, even if the hormonal changes of the body should be contradictory of the assigned sex. Thus, a boy who develops breasts and urethral bleeding, which is actually menstruation, is mortified by these “stigmata” of femininity, and wants to be rid of them. Conversely, a girl whose voice deepens and body hair masculinizes, also is mortified and wants to be rid of these unfeminine impediments.

By the normal age of puberty, the differentiation of gender identity has been well established as either masculine or feminine, or possibly as ambiguous, or as marred in some way by paraphiliac distortion. The erotic

status of gender identity at puberty is a product of childhood erotic rehearsal in fantasy and play, both of which will have been influenced by the erotic traditions and behavioral models to which the child has been exposed. They will also have been influenced by the inhibitions and sanctions against erotic fantasy and play to which the child has been exposed—particularly important in our cultural tradition which has a strong taboo on the normal erotic play of primate childhood.

The hormones of puberty do not determine the cognitive or imagistic content of eroticism as masculine, feminine, or otherwise. They activate or increase the frequency of activation of what is already there. More accurately, androgen does the activating, for it appears to be the libido-regulating hormone of both sexes, controlling the subjective feeling of sexual desire or urge to use the sexual organs brought to reproductive maturity at puberty. In normal males, the libidinal influence of androgen is not cyclic, as it is in women. During the phase of ovulation, when her estrogen level peaks, woman is more erotically compliant and acceptive than during the menstrual phase of her cycle. Then, she is more erotically outgoing and initiating.

### **Personal Erotic Arousal Imagery**

Most human beings at puberty discover that a certain content or program of imagery, perceptual and/or in fantasy, stimulates them to

maximum erotic arousal and optimal sexual performance. It usually includes the appearance of the partner. The visual component is typically more important for men than for women. Woman's arousal is initiated more in relationship to sentiment and the sense of touch.

The content of personal erotic arousal imagery is remarkably persistent over the span of a lifetime. It usually declares itself at puberty, but it may be masked by erotic inertia and inhibition if it conflicts with the individual's moral conceptions of sexual activity. Then, it may declare itself only later in life, perhaps released by an intense or traumatic emotional experience.

Once having declared itself, an individual's personal erotic arousal imagery tends not to change, neither to be inhibited, nor to be supplanted by an alternative of equal erotic potency. This resistance applies both to spontaneous change and to attempted change through therapy. Change is not actually impossible, but, like the experience of religious conversion, it tends to be unpredictable in the timing of its occurrence. Thus, it is not feasible to predict whether a man with a typical heterosexual arousal imagery will undergo a change and be arousable only by typical transvestite imagery. Likewise, it is not feasible to predict whether a transvestite will change to regular heterosexual imagery, although both types of change have been recorded.

The persistence and potency of personal erotic arousal imagery at puberty are responsible for the determination of some intersexuals to refuse a sex reassignment, and of others to obtain one. In one case history, for example, a teenager with a diagnosis of male hermaphroditism, decided to agree to take estrogen tablets and to undergo surgery that would externalize an internally opening vagina, which connected with a uterus from which menstruation could be induced. She did so in the hope that, having a vagina, menses, and feminine breasts, she might finally be able to accommodate to her official assignment as a girl. It had always been an equivocal rearing at best, and the crowning uncertainty was partial amputation, at the age of five, of a large phallus, without prior warning.

After the vaginal operation which proved highly successful from the surgical viewpoint, the girl discarded her estrogen tablets as soon as she saw evidence of breast enlargement. She did so, and became determined to live the rest of her life as a man, because neither the feminizing surgery, nor the female hormones, nor the brief amount of psychotherapy received, have lessened the intensity of her erotic imagery toward females, and toward one girlfriend and lover in particular. Subsequently, she preferred her life as a man, despite the fact that attempted plastic surgical reconstruction of a penis is always less than satisfactory. She possessed a totally adequate vagina, but the potency of her erotic imagery of only females as lovers made it useless to her.



## Transsexual Sex Reassignment

Psychically, there is only a thin dividing line between sex reassignment in a case of intersexuality, like the one just quoted, and a case of transsexualism without congenital sex-organ defect. Both could, in fact, be called transsexualism, although it is not yet customary to refer to an intersexual individual who wants a sex reassignment as a transsexual. The similarity between the two is that they both feel the conviction of having a gender identity that does not agree with the sex of assignment, and both feel the incongruity of being maximally sexually aroused by personal erotic imagery, perceptually and/or in fantasy, of persons living in the same sex as that to which they feel themselves to have been wrongly assigned. They both arrive at the resolution of their predicament by means of sex reassignment.

One difference between an intersexual and a transsexual resolved on sex reassignment is that the former is more likely to be embarrassed, ashamed, shy, and perhaps electively mute, whereas the latter is more brazen, insistent, manipulative, and even overtly deceitful in order to achieve his own ends. But the difference is not universal; there is some overlap. Another difference is that the transsexual has no identifiable anomaly of the reproductive system. In fact, he has no identifiable genetic, anatomic, or physiologic defect or abnormality that can be measured by today's techniques. The same is true both for female and male transsexuals. The most

likely site where some etiologic defect might be uncovered in the future is the brain, possibly in connection with a fetal hormonal effect. To illustrate, it is now known from animal experiments that certain barbiturates and antibiotic substances can cancel out the masculinizing effect of male hormone injections given to a pregnant animal for the experimental purpose of masculinizing the female offspring.

There may be lessons to learn here, by analogy, with respect to substances either ingested by pregnant human mothers, or otherwise influencing the hormonal equilibrium of pregnancy, which may either demasculinize the fetal male brain or, conversely, masculinize the fetal female brain. All such analogies are, at present, in the realm of science fiction. The empirical facts are not yet forthcoming, but the possibility of their undiscovered existence should not be overlooked in the attempt to understand the etiology of either transsexualism or any of the gender identity anomalies.

Until new information is discovered, the most likely explanation of the etiology of transsexualism is that its origins lie in the period of late infancy and early childhood when, presumably, something disturbs the normal process of gender identity differentiation. It is quite possible that gender identity differentiation can be disturbed only in selected, predisposed infants. For example, boys who have the extra X chromosome (47,XXY) of Klinefelter's

syndrome, constitute a population at risk for psychopathology of all types, which includes psychosexual pathology, which includes, it would appear, transsexualism of a frequency too high to be expected by chance alone.

For a second example, one may note the fact that a majority of male transsexuals, like extremely effeminate homosexuals, lack from infancy onward the assertiveness needed to establish a position in the dominance hierarchy of growing boys. This lack may be the end product of a fetal hormonal deficit resulting in an incompletely masculinized nervous system. By itself alone, such a deficit would not automatically lead to a transsexual development—no more so than the converse of tomboyish energy expenditure in a girl would do. However, the nonassertive male infant may be especially prone to interact with a particular type of parental social milieu, the outcome being transsexualism. The predictable formula has not yet been discovered. It seems likely that any major emotional disturbance in the family life, including such a nonsexual disturbance as death or dying in the household, as well as more obviously sexual problems as emotional distance between the parents, may have an adverse effect on the gender identity differentiation of some children.

### **Sex Reassignment: Rationale and Probationary Period**

The treatment of transsexualism by means of sex reassignment

resembles the treatment of congenital or traumatic organ defects by means of plastic surgery and mechanical prostheses. Both treatments represent the practice of ameliorative and rehabilitative medicine, the practice of choice in the absence of curative medicine. Broadly effective, widely available, and economically accessible methods of curative therapy have not yet been discovered for the gender identity disorders in general, and particularly not for the extreme forms like transsexualism. It is universally agreed that transsexualism is resistant to psychotherapy. Hence, no doubt, the reasonably widespread acceptance of sex reassignment therapy for transsexuals, despite initial controversy. Those who are against reassignment fear that it represents playing along with psychosis. The alternative view is that the organism, following the wisdom of the body, tries to heal its own injuries and traumas, and that there are occasions when medicine, having no better technique at its disposal, does best to respect that wisdom. Empirically, it happens that in a properly selected case, sex reassignment does improve a transsexual's over-all life situation.

To guarantee that a case is properly selected, it is best to require evidence that the person has actually lived in the sex of requested reassignment, establishing emotional, vocational, and financial autonomy, for a period of, preferably, two years. This is an admittedly difficult test for a transsexual to be put through with genital anatomy that belies civil status, but it is a necessary safeguard against a too hasty decision with future regret. No

matter how much a transsexual, male or female, feels convinced about the virtue of living as a member of the other sex, and no matter how satisfying the image of that life, or the occasional impersonation in it, there is no substitute for full-time experience. The reason is quite straightforward: No one can behave convincingly as either a man, or a woman, until experienced in being treated convincingly as such by other people in society at large, and acquainted at first hand with the disadvantages as well as the advantages. While appearing publicly as a man, a person does not, for example, know what it will be like to lose freedom of movement, unaccompanied, on the streets at night, as a woman—and so on.

A two-year probationary period serves also, in effect, as a preliminary period of social and hormonal rehabilitation. Hormonal therapy, by inducing changes in visible appearance, facilitates social rehabilitation. The majority of hormonal changes are reversible, should the probationary period lead to a change of prognosis and a decision against surgery, in which instance none of the changes is permanently disabling. In addition, hormonal changes have the advantage of helping to verify the differential diagnosis in borderline cases, before the irrevocable step of surgical reassignment is undertaken.

### **Differential Diagnosis**

The differential diagnosis lies between transvestism, transsexualism,

and homosexuality of extremely effeminate type in the male, or of extremely virilistic type in the female. In each instance, the individual will dress partially or completely in the clothes of the opposite sex on at least some occasions.

The transvestite does so episodically, in response to a feeling of intense psychic urgency to relieve a pent-up inner tension from which he cannot otherwise find respite. In this sense, he has an addiction to female clothing. His tension release is specifically related to sexual orgasm, insofar as the ideal ending to his cross-dressing episode is to have sexual intercourse while wearing items of feminine attire. Only then is he able to insure himself of the complete fulfillment of sexual abandon, or even to guarantee that he will keep an erection. With a partner whose own erotic response dies when she is trying to copulate with a man wearing female garments, his only method of success in intercourse while not cross-dressed may be to imagine himself as the woman, and his partner as the man. Unlike the effeminate male homosexual, he has no erotic resource for having sex with another male, although he probably has tried, or will try it, in a vain effort to find an alternative to his dilemma with women. His dilemma is that his erotic arousal is directed toward the female, if only she could accept him on his own transvestite terms; and that his erotic performance is not divorced from his own penis, despite the insistence of his obligation to dress in women's clothes and imagine himself as a woman. The transvestite who considers sex reassignment as a solution to his dilemma in life is rare. He is definitely a

person who benefits from a probationary period of a real-life test, in order to discover his proper decision.

Transvestism of the type just described in males, addictive in quality and prerequisite to coitus and orgasm, must be extremely rare in females, if it occurs at all, for it is not reported in the sexological literature. The explanation probably lies in the fact that all of the psychopathologies of sex, especially the more exotic and bizarre ones, occur either more frequently or exclusively in the male. Here, one perhaps sees an extension of the principle of sexual differentiation, namely, that nature's archetype is the female. The male requires something added—in psychosexual differentiation, apparently, as well as in morphologic differentiation. In the final additive stage, there is evidently an increased opportunity for something to go wrong in the psychosexual status of the male.

As compared with the bivalency of a transvestite's dressing in the clothing of both sexes, the homosexual with extreme contrasexual deviancy of gender role and identity has only one preferred way of dressing, namely, as close to the style of the other sex as possible. The limit is set by the tolerance of family, community, employer, and the law. According to currently acceptable fashion, there is more latitude for a lesbian to wear masculine clothing than vice versa, although by convention she should, like any women, visibly declare her femininity, no matter how masculine her styling.

The effeminate homosexual male, regardless of his history as a female impersonator in women's clothing, differs from the transsexual male in the erotic value his penis has to him. The capacity of his penis to achieve an orgasm is not inhibited, and he is not disgusted by penile orgasm as a sign of masculinity, as a transsexual may frequently be. The effeminate male homosexual may be impotent during a relationship with his male partner, but able to achieve orgasm alone afterwards. He enjoys the erotic relationship as the oral or anal recipient, nonetheless. He has no coital inclination toward using his own penis to insert into a vagina—or into a mouth or anus, for that matter. His erotic imagery does not require him to fantasy a female partner as a male, for the partner always is, in fact, a male with whom he can fantasy himself as feminine counterpart. Should an extremely effeminate homosexual happen to be on the borderline of transsexualism, then the two-year probationary period of living in a state of estrogenic impotence and non-orgasm will be essential to his arriving at a proper decision.

The probationary period is essential also for the virilistic lesbian on the borderline of transsexualism. For her, however, the ultimate surgical decision is not of quite identical import as for her male counterpart, since it does not entail the risk of diminution of erotic response. Androgen will increase the erotic response of her clitoris, not diminish it, and reconstructive surgery will entail its preservation, not obliteration. Yet, reconstructive surgery today cannot produce a coitally serviceable penis in a female, as it can a coitally



serviceable vagina in the male. The strongly virilistic lesbian fantasizes herself, in her sexual relationship with a girlfriend, as having a penis as she makes the thrusting movements of a man. From stimulating her clitoris in this way, and not from having her own vagina penetrated, which is anathema to her, she is able to bring herself to orgasm. Her primary surgical decision will involve not only her own body image with respect to mastectomy, hysterectomy, and attempted penile construction, but also the erotic attractiveness of her body to a sexual partner. A lesbian partner may abhor the lack of breasts and unfeminine genitalia, whereas a non-lesbian woman may be well satisfied with a flat chest, but not with imperfect male genitalia. The issue of how to be attractive to oneself and how to attract a partner, or else to be alone, is the one that needs the probationary period, in order to be resolved.

The transsexual male or female suitable for sex reassignment is, then, a person who has met the criterion of living as a member of the other sex for a probationary period of two years, more or less, before the final step of genital reconstruction is undertaken. He or she should be able to pass unnoticed in a crowd as a member of the new sex. In both cases, there will have been a history of gender identity ambiguity from an early age. This ambiguity may have shown itself overtly and consistently in childhood in the behavior of a feminized gender role in a boy, or a masculinized gender role in a girl. Alternatively, it may have been covert, as the child attempted to conform to the norm.

At puberty, acceptance of oneself as erotically different may have been overt, with no attempt to fake what seemed unnatural. Alternatively, there may have been an attempt to conform to the moral norm, punctuated by lapses into opposite-sexed behavior, in obedience to an ever-present fantasy and desire to do so permanently. The attempt to conform may have led to marriage and parenthood, neither of which, however, resolves the ambiguity of gender identity in the direction approved of by society. The female transsexual can have heterosexual intercourse as a gymnastic exercise, faking her way, so to speak, without positive erotic response. The male transsexual without positive erotic response cannot fake an erection, so he is less likely than his female counterpart to have had heterosexual coitus.

Both the male and the female transsexuals are likely to have tried homosexual intercourse by the time they apply for sex reassignment, though not inevitably so. Some transsexuals, especially males, exhibit not only an inhibition of the gender identity appropriate to their morphologic sex of birth, but also an inhibition of any erotic role associated with that identity. Thus, a male transsexual may be unable to engage in any form of sexual activity with a man while he still has his own masculine genitalia. Such behavior would be morally reprehensible to him, and repulsive. Even masturbation may be impossible, so intense is the phobia of the penis. A masturbation fantasy of himself as a woman is not powerful enough to cancel out the phobia of the male organ itself. The male transsexual with this extreme degree of avoidance

of his genitalia views reassignment in romantic rather than coital terms, and he may actually end up in the role of a spinster.

The male transsexual who does have sexual relations with a boyfriend prior to reassignment typically does not get an erection, and does not want to. He does not even want his penis to be seen by his partner, and certainly not touched. A male transsexual, prior to reassignment, may live by impersonating a female prostitute. He becomes adept at hiding his penis completely, with a technique of binding it between the legs or against the abdominal wall. He can safely predict that it will not erect, as he talks a customer into oral or anal coitus, or has him sufficiently inebriated that he scarcely knows what he is doing.

The male transsexual's conception of woman's sexuality is the conventional one of feminine passivity. In his feminine role, either before or after surgical reassignment, it is far more important to satisfy the partner than the self. Thus, the male transsexual does not capitalize on his male orgasm while he has it, and does not miss it when it is gone. After surgery, in the feminine role, a climactic experience may be reached; otherwise, the feeling of a diffuse, warm glow of eroticism is accepted as more than adequate compensation for the ability to love a man as a woman loves him.

A female transsexual may have an extensive phobia of her female

genitalia, but the clitoris is likely to be excepted, being to her a proto-type penis. She is more likely to have had active love affairs as a dominant lesbian than her male counterpart is likely to have had as a submissive homosexual. She may use a strap-on prosthetic penis, but would refuse the penetration of anything into her own body. Her breasts to her are almost certainly the mortifying part of her body, corresponding to the penis of the male homosexual. Her body image, as judged from posed snapshots, is that of a male athletic model or weightlifter, posing with tightened muscles. So she binds her breasts, and does not want them seen or touched, even by her lover.

### **Hormonal Reassignment: Male**

For the post-adolescent male, estrogen will bring about a functional castration which, while having the safeguard of being reversible, will acquaint the recipient at first hand with the subjective experience of loss of potency and reduction of libido, both of which are consistent with the male transsexual's phobic avoidance of his own genitalia. Estrogen will also promote proliferation of mammary duct tissue with variable individual success. Although this effect is not totally reversible upon withdrawal of estrogen, it can be readily reversed surgically. Estrogenic therapy does not arrest the growth of body or facial hair already established, although it does retard the speed of growth and makes wiry hair more silky. Electrolysis is necessary for complete removal of facial hair. Although the larynx does not

change under the influence of estrogen, vocal mechanics are so modulated in the majority of transsexuals as to sound femininely husky, instead of masculinely deep-toned—and consistently so, without lapses. The surface appearance of the body becomes more femininely adipose under the influence of estrogen-induced subcutaneous fat distribution; but narrow hips do not broaden after the bone shape has been set by epiphyseal closure.

Because of the irreversibility of adolescent masculinization of bone, hair, and voice, it is highly desirable in the case of a virilizing intersexed child not to postpone reassignment therapy as a female, once the psychologic and psychiatric examination has confirmed the advisability of the decision. In similar fashion, it is desirable not to temporize in instituting feminizing therapy in the case of an intersexed child reared and living as a girl with a female gender identity, if she commences to undergo a masculinizing puberty—even if the diagnosis is one of male hermaphroditism. The day may come when this same principle of preventing pubertal masculinization will be applied to the extremely effeminate transsexual boy at the age of puberty. At the present time, however, those who work with transsexualism prefer to accumulate more statistics on outcome in older patients, before lowering the age of treatment. The same applies to masculinization of the transsexual girl.

The most up-to-date schedule of medication for the male transsexual, recommended by Claude Migeon in an unpublished personal communication,

is as follows:

Diethylstilbestrol—0.25 to 0.50 mg. daily with Provera (medroxyprogesterone acetate) 2.5 to 5.0 mg. daily.

In place of Diethylstilbestrol, Estinyl (ethinyl estradiol) 0.02 to 0.05 mg. daily, or Premarin (conjugated equine estrogens) 1.25 to 2.50 mg. daily might be substituted. Before gonadectomy, the treatment would be every day for a minimum of four to eight months. Following surgery, treatment could be cyclic, for the first three weeks of each month, missing the fourth week.

An alternative to the foregoing combination of estrogen plus progestin taken separately would be a commercial product combining the two, for example:

Ortho-Novum 1 mg. (norethindrone 1 mg. and mestranol 0.05 mg.), or Norlestrin, 1 mg. (norethindrone acetate x mg. and ethinyl estradiol 0.05 mg.), or Provest (Provera 10 mg. and ethinyl estradiol 0.05 mg.). The dosage of these preparations is one tablet daily for the first three weeks of each month.

If the patient prefers not to accommodate to a daily oral therapy, but to an intramuscular one instead, then the following could be prescribed: Delestrogen (estradiol valerate) 5-20 mg. plus Delalutin (hydroxyprogesterone caproate) 62.5-125 mg. every two weeks. Another

intramuscular combined treatment could be: Depo-Estradiol cypionate 1-5 mg. plus Depo-Provera 25-100 mg. every two weeks.

After four to eight months of biweekly therapy, the same dosages could be given once every three or four weeks.

If in the preoperative state, the above dosages prove insufficiently effective after four to six weeks, then the dosage could be doubled. Otherwise, the rule is to use the dosage that is thought presently to be replacement therapy for normal women. For further details concerning hormonal treatment of the male, see Green and Money.

### **Hormonal Reassignment: Female**

For the post-adolescent transsexual female given androgenic therapy during the probationary period, the first effect will be to suppress the menses. Since eventually breakthrough bleeding will occur, permanent suppression requires hysterectomy as well. Androgen will also induce deepening of the voice through lengthening of the vocal cords. This effect is not reversible, except insofar as the voice may be pitched in its higher, huskier register, instead of its deeper more resonant one. Androgen-induced growth of facial and body hair is also nonreversible, except by electrolysis. Androgen does not completely atrophy the breasts, so that the chest can be flattened only surgically, by mastectomy. The clitoris undergoes some enlargement under

androgen stimulation, perhaps to three times its original size, but never to be large enough for surgical reconstruction as a penis.

In the volume by Green and Money may be found details for hormonal treatment of the female transsexual. Migeon recommends 100 to 300 mg. of testosterone enanthate, intramuscularly, every three or four weeks. This treatment does not prevent menopause-like symptoms following ovariectomy. Control of such symptoms requires estrogenic therapy, with gradual withdrawal over a period of three to six months.

### **Psychological and Psychiatric Guidance**

Sex reassignment does not, of and by itself alone, solve psychological problems over and beyond the problem of gender identity. Thus, if there is an associated problem of unresolved suicidal depression, the need for psychiatric care will continue after reassignment. Likewise, if there is an associated problem of psychopathic delinquency, lying, and stealing, continued therapy for that problem will be needed. Controversy surrounds the issue of associated schizophrenic disorder, for there are some who would see all transsexualism as schizophrenia, or possibly as paranoia transsexualis. To equate transsexualism and schizophrenia is, however to muddy the language unnecessarily. It also confuses the issue of treatment, for there are some cases of transsexualism associated with symptoms of schizophrenia and



paranoia, as conventionally diagnosed. In these cases, sex reassignment does not guarantee a lifting of associated psychiatric symptoms. Sex reassignment plus assiduous psychotherapy may eventually produce a positive outcome, but there is insufficient evidence for a definitive statement at the present time.

In psychiatrically uncomplicated cases, the amount of guidance needed during the probationary period and after may be remarkably little. In those cases where more help is needed, it is wise to have it readily available, so that intervention can be undertaken on a preventive basis, keeping the troubles from multiplying.

It is good preventive therapy to involve also, wherever possible, the families. One insures thereby not only a source of additional case-history information and possible validation of the transsexual's own story, but also an extra source of social support in rehabilitation.

Parents and other family members benefit from whatever help can be given them in dealing with a difficult hurdle in life, that may, nonetheless, offer them the first chance of respite in years.

### **Surgical Treatment**

The technical details of transsexual surgery are subject to continued

revision and improvement. To keep up to date, the specialist reader should consult the surgical literature. Here, it is appropriate to outline only the general principles.

In the male, the skin of the penis and of part of the scrotum is preserved for use in plastic-surgical feminization. The body of the penis is excised. The urethral tube is shortened and implanted in the feminine position. A vaginal cavity is opened up in the musculature of the perineum and fitted with a skin-graft lining made from the skin of the penis. This lining may be prepared by first amputating the penis and removing its skin like removing a condom. Alternatively, prior to excision of the body of the penis, the skin may be dissected free in the form of an apron-graft left hanging from the abdominal wall. From this apron, plus a flap from the scrotal skin, a tubular vaginal lining is sewn, augmented in size by an insert of skin grafted from the thigh.

The latter technique preserves part of the original blood supply and neural innervation, and allows greater flexibility in the deployment of scrotal skin for a more capacious artificial vagina to be formed, whereas the former dictates that the size of the vagina is more directly determined by the size of the penis. A very small penis produces a vagina too small for successful coitus. In either case, some of the scrotal skin is used for the creation of labia majora. This may be postponed until a second operation, if a period of healing from the first is needed to establish a good blood supply. Post-surgically, a form

needs to be kept in place in the newly created vagina, especially during the healing period and prior to regular coital activity, to insure its patency.

Erotically, the artificial vagina supplies a male partner with satisfying sexual feelings. The person with the artificial vagina also enjoys sexual intercourse, experiencing a pervasive warm glow of erotic feeling and, in some instances, a peak or climactic feeling that corresponds to the orgasm of former days—had such been experienced, which is not always the case—though not identical with it.

Masculinizing plastic surgery of the genitalia for the female transsexual is as difficult as the same type of surgery for the boy born with no penis or the man who has suffered traumatic loss of his organ. It is a procedure not to be undertaken lightly. It requires multiple hospital admissions, the exact number being unpredictable, and may take literally years—to say nothing of expense. The end result is a soft cylinder of skin, functional for urination but too soft for intercourse. Surgical implantation of silicone stiffeners has so far not proved successful. For successful intercourse, the skin-graft penis of plastic surgery needs to be inserted in a hollow dildo made of synthetic plastic. This gives satisfaction to the female partner, as an extension of varied techniques of love play. The transsexual himself receives erotic feeling and the build-up to orgasm from the tissues of the former clitoris, now imbedded in the wall of the skin-graft penis. Since the clitoris and the shell-dildo are the essential

components of a mutually satisfying erotic experience, the female-to-male transsexual is well advised to forego the colossal burden of surgery and to be satisfied with only a strap-on penis. Some are capable of utilizing this advice, but others are driven relentlessly to having even an imperfect organ attached permanently to their own bodies.

The surgical technique for creating this organ begins with making a tubular roll of skin on one side of the abdominal wall. At the conclusion of the first operation, this roll resembles the handle of a briefcase, since both ends remain attached to insure continuity of blood supply. After the first-stage healing is complete, the top attachment is severed, and the end of the “handle” is implanted just below the clitoris. The other end is released later. Other aspects of the surgery are the creation of a urethral tube, excision of the vagina (and, of course, panhysterectomy), and conjunction of the urinary outlet with the urinary tube in the new penis.

### **Gender Identity Differentiation: Hypothesis**

From transsexualism it is evident that gender identity can differentiate in frank contradiction of the reproductive genitalia and post-pubertal appearance of physique. From cases of intersexuality one learns that chromosomal and gonadal sex may be deliberately disregarded in deciding the sex of assignment, so that one is, in a limited and specific sense, inducing

iatrogenic homosexuality, according to the chromosomal and gonadal criteria, but not the external-genital and other criteria of homosexuality. Moreover, one may pair such cases with matching ones for whom the sex of assignment was the opposite. Then, one has two individuals of matching etiology and diagnosis who differentiate opposite gender identities. Thus, both spontaneously and by iatrogenic design, one has evidence of discontinuity between gender identity and one or more other variables of sex, where normally there is continuity. Obviously, gender identity differentiation in its postnatal phase is highly malleable and not preordained. It is open to social contingencies, as is language, and as is imprinting of the type demonstrated in ethological studies.

Up until the present, it has been the theoretical fashion to consider the social contingencies of gender identity differentiation only in terms of reinforcement for copying role models of the same sex, but not for neglecting or omitting to copy models of the other sex. That both processes occur, the negative as well as the positive, is made evident in the lives of people who eventually want a sex reassignment. To catch the evidence, it is necessary to engage in longitudinal study. Then, one may be rewarded with a glimpse of a time in development when a child is able to alternate from a masculine to a feminine way of doing things, and vice versa. Later, the pendulum swings, and gender behavior, and identity with it, becomes unitary. The swinging of the pendulum can be seen and heard, and recorded on videotape, in some young

transsexuals. They can call on the two systems of behavior, masculine and feminine, and put them into action, at a time when their normal contemporaries cannot. Persistent availability of the two systems into adulthood can be seen particularly well in typical transvestites, who have two names, two wardrobes, and two personalities, all matching as male and female, respectively. The difference between the two personalities, and the consistency of each, the one masculine and the other feminine, is as great as the difference between two completely separate individuals of different sex.

In such cases of transvestism, one has, in fact, an equivalent of multiple personality. The possibility that the transvestite is different from the majority of people only in keeping his two personalities on call, is suggested by some rare reports in the neurosurgical literature. These are reports of transvestism and/or fetishism, in which the disturbance of gender behavior came to the fore when temporal lobe epilepsy manifested itself. Following temporal lobectomy, both the epileptic seizures and the transvestism no longer occurred. Even without seizures, it is rare for transvestism to manifest itself *de novo* in adult life, but it is known to have done so—again suggesting that a system once irretrievable from memory storage becomes retrievable and transmittable into action.

In view of the foregoing evidence, it makes good sense to postulate that gender identity differentiation is for all human beings a process constituted of

coding both the masculine and the feminine systems of gender role. The double coding permits one system to be segregated from the other, negatively coded, and called upon only to verify what to exclude from the positively coded system. In other words, a boy knows how to be a boy, because he knows how not to be a girl, and vice versa for girls.

This dual system is analogous with that of two native languages. The bilingual child learns best if the carriers of the two languages are different persons. Each language then becomes linked to a different person, or persons, with overlap minimized. So also with gender identity, the carriers of the two systems are segregated. Again, a bilingual child may use both languages throughout life, but he may also inhibit one, attaching to it a sense of shame, as in the case of an immigrant's child who is ashamed of the old-country ways of his parents.

The factors that allow one child to differentiate a unitary gender identity in the expected direction, whereas another differentiates incompletely, perhaps finally swinging in the inappropriate direction, remain a challenge to research. So also does the explanation of why gender identity, once differentiated, remains singularly immutable, when it is congruous, as well as when it is incongruous with whichever criteria of sex one may be using.

## Concluding Remarks

Intersexuality is theoretically important to psychiatry in demonstrating that the differentiation of gender identity is not preordained by genetic or chromosomal sex directly, nor by fetal hormonal sex. Fetal androgen, however, is an important contributor in that its presence induces masculinization of the external genitals and of certain hypothalamic functions, both of which otherwise differentiate as female. The external genital appearance profoundly influences the behavior of others from the time of sex assignment throughout rearing, and also the individual's own body image and self-conception. The hormone-differentiated hypothalamus probably influences such sexually dimorphic behavioral differences as energy expenditure level, pelvic thrusting movements in childhood play, and dominance assertiveness in the power hierarchy of childhood play. In human beings, postnatal differentiation of gender identity is not preordained by prenatal hormonal influences, though it may be influenced by them. Postnatal differentiation, like language acquisition, requires social interaction. It may issue in a gender identity that is congruent with its antecedents, contradictory to them, or ambiguous.

Postnatal gender identity, once differentiated, is singularly tenacious in maintaining itself. For this reason, the decision concerning an intersexed child's sex assignment should be fixed at the time of birth. If later



considerations lead to a revision of diagnosis and the possibility of sex reassignment, then more attention should be given to the status of the gender identity already differentiated than to the other variables of sex. Psychological failure of sex reassignment in intersexuality is guaranteed unless gender identity has been incomplete or ambiguous in the sex of assignment. It is most successful if the intersexed child has already reached a resolution for sex change.

The success of sex reassignment in specific and highly selected cases of intersexuality is paralleled by its success also in selected cases of transsexualism. The basic difference between the two cases is that the typical transsexual has no visible or measurable signs of abnormality of the reproductive system. His or her condition is, if the term intersexuality is to be applied at all, one of psychic intersexuality. It is best to precede surgical sex reassignment in transsexualism by a two-year probationary period of living full time in the new role.

Theoretically, the anomalies of gender identity might best be understood through the hypothesis that all human beings have both a masculine and feminine pattern of gender behavior coded in the brain, one of them usually negatively coded, the other positively. The anomalies of gender identity represent an imbalance of the usual positive-negative ratio. The process of becoming a boy is by identification on the reciprocal process of not

becoming a girl, but knowing how to respond to females is by complementation, for girls the obverse holds true.

## Bibliography

Benjamin, H. *The Transsexual Phenomenon*. New York: Julian Press, 1966.

Davies, B. M., and F. S. Morgenstern. "A Case Of Cysticercosis, Temporal Lobe Epilepsy, and Transvestism," *Journal of Neurological and Neurosurgical Psychiatry*, 23 (1960), 247-249.

Epstein, A. W. "Fetishism: A Study of its Psychopathology with Particular Reference to a Proposed Disorder in Brain Mechanisms as an Etiological Factor," *Journal of Nervous and Mental Disease*, 130 (1960), 107-119.

----. "Relationship of Fetishism and Transvestism to Brain and Particularly to Temporal Lobe Dysfunction," *Journal of Nervous and Mental Disease*, 133 (1961), 247-253.

Federman, D. D. *Abnormal Sexual Development, a Genetic and Endocrine Approach to Differential Diagnosis*. Philadelphia: Saunders, 1967.

Gardner, L. I. *Endocrine and Genetic Diseases of Childhood*. Philadelphia: Saunders, 1969. (2nd ed., 1974, in press.)

Gorski, R. "Gonadal Hormones and the Perinatal Development of Neuroendocrine Function," in L. Martini and W. F. Gonong, eds., *Frontiers in Neuroendocrinology*. New York: Oxford University Press, 1973.

----. "Localization and Sexual Differentiation of the Nervous Structures which Regulate Ovulation," *Journal of Reproduction and Fertility*, Supplement 1 (1966), 67-88.

Goy, R. W. "Role of Androgens in the Establishment and Regulation of Behavioral Sex Differences in Mammals," *Journal of Animal Science*, 25 (1966), 21-35.

- Green, R., and J. Money, eds. *Transsexualism and Sex Reassignment*, pp. 305-307, 353-354. Baltimore: Johns Hopkins Press, 1969.
- Harris, G. W. "Sex Hormones, Brain Development and Brain Function," *Endocrinology*, 75 (1964)-627-648.
- Jones, H. W. Jr. and W. W. Scott. *Hermaphroditism, Genital Anomalies and Related Endocrine Disorders*. Baltimore: Williams and Wilkins, 1958. (2nd. ed. 1971.)
- Mitchell, W., M. A. Falconer, and D. Hill. "Epilepsy with Fetishism Relieved by Temporal Lobectomy," *Lancet*, 2 (1954), 626-630.
- Money, J. "Determinants of Human Sexual Identity and Behavior," in C. J. Sager and H. S. Kaplan, eds., *Group and Family Therapy*, New York: Brunner/Mazel, 1972.
- . "Hermaphroditism and Pseudohermaphroditism," in J. J. Gold, ed., *Textbook of Gynecologic Endocrinology*. New York: Harper and Row, 1968. (2nd ed., 1974, in press.)
- . "Influence of Hormones on Sexual Behavior," in A. C. Degraff, ed., *Annual Review of Medicine*, Vol. 16. Palo Alto, California: Annual Reviews, Inc., 1965.
- . "Matched Pairs of Hermaphrodites: Behavioral Biology of Sexual Differentiation from Chromosomes to Gender Identity," *Engineering and Science* (California Institute of Technology), 33 (1970), 34-39.
- . *Sex Errors of the Body*. Baltimore: Johns Hopkins Press, 1968.
- , ed. *Sex Research: New Developments*. New York: Holt, Rinehart and Winston, 1965.
- . "Sexual Dimorphism and Homosexual Gender Identity," *Psychological Bulletin*, 74 (1970), 425-440.
- , and A. A. Ehrhardt. *Man and Woman Boy and Girl: The Differentiation and the Dymorphism of Gender Identity from Conception to Maturity*. Baltimore: The Johns Hopkins Press, 1972.

- Money, J. and R. Gaskin. "Sex Reassignment," *International Journal of Psychiatry*, 9 (1970-71), 249-282.
- Money, J., R. Potter and C. S. Stoll. "Sex Re-announcement in Hereditary Sex Deformity: Psychology and Sociology of Habilitation," *Social Science and Medicine*, 3 (1969), 207-216.
- Newton, N. *Maternal Emotions. A Study of Women's Feelings Toward Menstruation, Pregnancy, Childbirth, Breast Feeding, Infant Care, and Other Aspects of Their Femininity*. New York: Hoeber, 1955.
- Nielsen, J. "Klinefelter's Syndrome and the XYY Syndrome: A Genetical, Endocrinological and Psychiatric-Psychological Study of Thirty-Three Severely Hypogonadal Male Patients and Two Patients with Karyotype 47,XYY," *Acta Psychiatrica Scandinavica*, Vol. 45, Supplementum 209, Copenhagen: Munksgaard, 1969.
- Nielsen, J., A. Sørensen, A. Theilgaard, A. Frøland, and S. G. Johnsen. "A Psychiatric-Psychological Study of 50 Severely Hypogonadal Male Patients, Including 34 with Klinefelter's Syndrome, 47,XXY," *Acta Jutlandica*, 41, No. 3. Publications of the University of Aarhus, Copenhagen, Munksgaard, 1969.
- Overzier, C., ed. *Intersexuality*. New York: Academic Press, 1963.
- Stoller, R. J. *Sex and Gender, On the Development of Masculinity and Femininity*. New York: Science House, 1968.
- Whalen, R. E. "Differentiation of the Neural Mechanisms Which Control Gonadotropin Secretion and Sexual Behavior," in M. Diamond, ed., *Reproduction and Sexual Behavior*. Indiana University Press, 1968.
- Wilkins, L. *The Diagnosis and Treatment of Endocrine Disorders in Childhood and Adolescence*. Springfield, Ill.: Charles C. Thomas, 1965.

## Notes

- 1 The first use of this word in print was: Caldwell D. O. (1949) Psychopathia Transexualis. *Sexology*,

16:274-280. Caldwell also used the English form, transsexual, with one “s.”

In ordinary English one has the parallel orthography with one “s” in transcribe, transect, transistor, transonic, etc.

In medical orthography, one has transsternal, trans-sacrum, etc.; and transection as an alternate to transection.

My policy is to have transsexual as an allowable alternate to the preferred spelling, transsexual. This keeps the spelling as simple as possible, and also is in keeping with the fact that transsexual is not specifically a medical term, but belongs to the general vocabulary.

Many books and articles (my own included) now use the preferred spelling, transsexual; and the Erickson Education Foundation, sponsor of transsexual research, has officially adopted that spelling.

[2](#) Consult items 5, 6, 12, 18, 27, and 30 in the Bibliography for detailed information concerning etiology, diagnosis, treatment, and prognosis, of the various types of intersexuality and hermaphroditism. (The two terms are nowadays used synonymously.) no vaginal cavity is present, the construction of one by means of plastic surgery is best postponed until after full growth has been achieved in middle-to-late teenage.